

Dental Journal

Majalah Kedokteran Gigi

EDITORIAL BOARDS OF DENTAL JOURNAL (MAJALAH KEDOKTERAN GIGI)

SK: 04/UN3.1.2/2015

January 2nd – December 31st, 2015

Patron:

Dean of Faculty of Dental Medicine, Universitas Airlangga

Advisors:

Vice Dean I, Vice Dean II, Vice Dean III

Chief Editor:

Ketut Suardita, drg., Ph.D., Sp.KG

(Department of Conservative Dentistry - Faculty of Dental Medicine, Universitas Airlangga)

Editorial Boards:

Prof. Dr. Pinandi Sri Pudyani, drg., SU., Sp.Ort(K) (Department of Orthodontics - Faculty of Dentistry, Universitas Gadjah Mada); **Prof. Dr. Anita Yuliati, drg., M.Kes** (Department of Dental Material – Faculty of Dental Medicine, Universitas Airlangga); **Prof. Dr. Jenny Sunariani, drg., MS** (Department of Oral Biology- Faculty of Dental Medicine, Universitas Gadjah Mada); **Prof. Dr. Adioro Soetojo, drg., MS., Sp.KG(K)** (Department of Conservative Dentistry- Faculty of Dental Medicine, Universitas Gadjah Mada); **Prof. Dr. Sri Kunarti, drg., MS., Sp.KG(K)** (Department of Conservative Dentistry- Faculty of Dental Medicine, Universitas Gadjah Mada); **Prof. Dr. Diah Savitri Ernawati, drg., M.Si., Sp.PM(K)** (Department of Oral Medicine - Faculty of Dental Medicine, Universitas Airlangga); **Kus Harijanti, drg., MS., Sp.PM(K)** (Department of Oral Medicine - Faculty of Dental Medicine, Universitas Airlangga); **Dr. Chiquita Prahasanti, drg., Sp.Perio(K)** (Department of Periodontics - Faculty of Dental Medicine, Universitas Airlangga); **Dr. Retno Indrawati, drg., M.Si** (Department of Oral Biology- Faculty of Dental Medicine, Universitas Gadjah Mada); **Dr. Retno Pudji Rahayu, drg., M.Kes** (Department of Oral Pathology and Maxillofacial - Faculty of Dental Medicine, Universitas Airlangga); **Dr. Theresia Indah Budhy, drg., M.Kes** (Department of Oral Pathology and Maxillofacial - Faculty of Dental Medicine, Universitas Airlangga); **Dr. Indah Listiana Kriswandini, drg., M.Kes** (Department of Oral Biology- Faculty of Dental Medicine, Universitas Gadjah Mada); **Dr. Ernie Maduratna Setiawati, drg., M.Kes., Sp.Perio(K)** (Department of Periodontics - Faculty of Dental Medicine, Universitas Airlangga); **Dr. Agung Krismariono, drg., M.Kes., Sp.Perio** (Department of Periodontics - Faculty of Dental Medicine, Universitas Airlangga); **Dr. Pratiwi Soesilowati, drg., M.Kes** (Department of Oral Biology- Faculty of Dental Medicine, Universitas Gadjah Mada); **Wisnu Setyari, drg., M.Kes** (Department of Oral Biology- Faculty of Dental Medicine, Universitas Gadjah Mada)

Managing Editors:

Dr. Susy Kristiani, drg., M.Kes (Department of Odontology Forensic – Faculty of Dental Medicine, Universitas Airlangga); **Priyawan Rachmadi, drg., Ph.D** (Department of Dental Material – Faculty of Dental Medicine, Universitas Airlangga); **Udijanto Tedjosongko, drg., Ph.D., Sp.KGA** (Department of Pediatric Dentistry – Faculty of Dental Medicine, Universitas Airlangga); **Dr. Hendrik Setia Budi, drg., M.Kes** (Department of Oral Biology – Faculty of Dental Medicine, Universitas Airlangga); **Sianiwati Goenharto, drg., MS** (Department of Orthodontics – Faculty of Dental Medicine, Universitas Airlangga); **Dr. Anis Irmawati, drg., M.Kes** (Department of Oral Biology – Faculty of Dental Medicine, Universitas Airlangga); **Yuliati, drg., M.Kes** (Department of Oral Biology – Faculty of Dental Medicine, Universitas Airlangga); **Eric Priyo Prasetyo, drg., M.Kes., Sp.KG** (Department of Conservative Dentistry – Faculty of Dental Medicine, Universitas Airlangga)

Administrative Assistant:

Novi Dian Prastiwi (Faculty of Dental Medicine, Universitas Airlangga)

Editorial Address:

Faculty of Dental Medicine Universitas Airlangga
Jln. Mayjen. Prof. Dr. Moestopo No. 47 Surabaya 60132, INDONESIA
Telp. (062-31) 5039478/ 5030255. Fax. (031) 5039478/ 5020256
E-mail: dental_journal@yahoo.com; Website: www.e-journal.unair.ac.id/index.php/MKG

Accredited No. 56/DIKTI/Kep/2012

Cover photo purchased from: www.fotolia.com
Invoice number: 206803056-204225738

Dental Journal

Majalah Kedokteran Gigi

CONTENTS

	<i>Page</i>
1. Xerostomia severity difference between elderly using alcohol and nonalcohol-containing mouthwash Hendri Susanto	109–112
2. Serum C-reactive protein and C-reactive gene (-717C>T) polymorphism were not associated with periodontitis in Indonesian male patients Suhartono AW, Sulijaya B, Djamal NZ, Masulili SLC, Talbot C, and Auerkari EI	113–118
3. Potential of <i>Jatropha multifida</i> sap against traumatic ulcer Basri A. Gani, Abdillah Imron Nasution, Nazaruddin, L. Sartika, and Rahmat K. Alam	119–125
4. Comparison between probiotic lozenges and drinks towards periodontal status improvement of orthodontic patients Natasia Melita Kohar, Victor Emmanuel, and Luki Astuti	126–129
5. Correlation between magnesium and alkaline phosphatase from gingival crevicular fluid on periodontal diseases Kasuma N. and Lipoeto I.	130–134
6. Apoptosis of <i>Rattus norvegicus</i> gingival fibroblasts caused by silver nano-particles gel exposure Kharinna Widowati, Titiék Berniyanti, and Retno Pudji Rahayu	135–138
7. Autogenous tooth transplantation: an alternative to replace extracted tooth 139 David B. Kamadjaja	139–143
8. The effect of ethyl acetate fraction of Citrus limon peel on mesenchymal cell proliferation and polybacterial growth Astrid Marinna, Priyo Hadi, and Desiana Radithia	144–149
9. The effect of 25% Mauli banana extract gel to increase the epithel thickness of wound healing process in oral mucosa Maharani Laillyza Apriasari, Ariska Endariantari, and Ika Kustiyah Oktaviyanti	150–153
10. Experimental comparative study and fracture resistance simulation with irrigation solution of 0.2% chitosan, 2.5% NaOCl and 17% EDTA Ernani, Trimurni Abidin, and Indra	154–158
11. VEGF expression and new blood vessel after dental X-ray irradiation on fractured tooth extraction wound Niluh Ringga Woroprobosari, Jenny Sunariani, and Eha Renwi Astuti	159–164

Apoptosis of *Rattus novergicus* gingival fibroblasts caused by silver nano-particles gel exposure

Kharinna Widowati,¹ Titiek Berniyanti,² and Retno Pudji Rahayu³

¹ Department of Oral Medicine, Faculty of Dentistry, Universitas Hang Tuah

² Department of Dental Public Health, Faculty of Dental Medicine, Airlangga University

³ Department of Oral Pathology and Maxillofacial, Faculty of Dental Medicine, Airlangga University
Surabaya – Indonesia

ABSTRACT

Background: The use of silver nanoparticle are growing, especially in medical science, it's used in many concentration. In dentistry, it's used to decrease halitosis, and periodontal diseases, and wound healing. It can affect the viability of the cells, give bad effects to the human's health and environment if used in a long duration and in certain concentration. **Purpose:** The purpose of this study was to learn the apoptosis of gingival fibroblasts in *Rattus novergicus* which is exposed with 15 µg/ml silver nano-particle gel by the expression of caspase-3. **Methods:** This study used 9 male wistar rats and were divided into 3 groups. Sample in group A were cut (hurt) in the oral gingiva and exposed to Ag-Np gel 15 µg/ml for 3 days. After 3 days, they were sacrificed and cut the gingival fibroblasts off 3x4 cm size with scalpel. Samples in group B were cut in the oral gingiva and exposed to Ag-Np Gel 15 µg/ml for 5 days. After 5 days they were sacrificed and the gingival fibroblasts off 3 x 4 cm with a scalpel. Samples in group C were cut in the oral gingiva and exposed to none for 3 days then cut the gingival fibroblasts off 3 x 4 cm size with scalpel. The expressions of caspase-3 in the apoptotic and wound healing process were analyzed by Immunohistochemical test. This data was analyzed by using the t-test method. **Results:** Mean expression numbers of caspase-3 in the group A = 5.67; group B = 11.33; and group C (control) = 18.67. T-test sign.number of group A and C = 0.009; group B & C = 0.000. **Conclusion:** The exposure of 15 µg/ml silver gel nanoparticle to gingival fibroblasts of *Rattus novergicus* reduces the expressions of caspase-3 in the day-3 and day-5 post exposure. The amounts of cell death through the apoptotic pathway which were analyzed by the expressions of caspase-3 will decrease too.

Keywords: Apoptotic; silver; nano-particles; caspase-3

Correspondence: Kharinna Widowati, c/o: Departemen Ilmu Penyakit Mulut, Fakultas Kedokteran Gigi Universitas Hang Tuah. Jl. Arif Rahman Hakim 150 Surabaya 60111, Indonesia. E-mail: kharinna.widowati@gmail.com

INTRODUCTION

The use of silver reminds us of the luxury culture in Greek, Roman, and Egyptian. Silver is well-known type of metal and ranks number third after gold and silver copper in those nations.¹ Silvers are generally used for water containers and the other liquid materials to keep the cleanliness and sterility.²

Silver use has developed very fast for health purpose. The Macedonians use silver to prevent infection after surgery. Aside from being antiseptic, Hippocrates used the preparation of silver nitrate for ulcer treatments, compound fractures, and a good wound healing supporting material.¹

Avicenna use silver nitrate to purify blood, to prevent heart palpitation, and to handle respiratory diseases. In 1880, Doctor Carl Siegmund Franz Crede, a German obstetrician, became the first person to use eye drops made from 1% silver nitrate to prevent ophthalmia neonatorum (gonorrhoeal ophthalmia) on babies.³ Anti-bacterial function of silver nano-particles are also utilized by the dentists as mouthwash therapy for periodontal diseases, to reduce bad breath, to help wound healing process and to prevent infection in tooth extraction and surgery.⁴

The use of silver nano-particles progresses rapidly in the field of nanobiotechnology; however, silver nano-particles also have negative consequences to human and environment

for prolonged use or in uncontrollable concentration.⁵ Silver particles have a nano size because they can easily fit into cells. Therefore, if silver nano-particles are used continuously with uncontrollable concentrations, they can lead to cells death and affect human biological system.⁶

Several studies have been conducted to examine the effect of silver nano-particles use on rats liver cells. The result showed that the use of silver nano-particles with 5-10 µg/ml concentration can affect the decline of mitochondrial function and the integrity of liver cell membranes after 24 hours incubation.⁷ The other in vitro studies, 24-48 hours exposure of silver nano-particles with 10-25 µg/ml concentration on human lung cells fibroblasts can stimulate the release of pro-inflammatory cytokines as the oxidative stress level and reactive oxygen species (ROS) production are proliferated that can potentially damage DNA cells.⁸ This implies that some information about the other effects caused by the use of silver nano-particles with concentration circulated in the market are needed so that people will be more vigilant in using silver nano-particles.

Based on the data above, we conducted a deeper research by using gingival fibroblasts cells of *Rattus novergicus* as the subject test because their tissues are similar to human gingival fibroblasts cells that potentially get exposed directly when the application process of silver nano-particles was done topically. The purpose of this study was to examine the death of *Rattus novergicus* gingival fibroblasts cells through apoptosis by analyzing caspase 3 expression.

MATERIALS AND MTHODS

This study is experimental laboratory with post test only control group design. This study was conducted in the laboratory of Biochemistry and Pathology, Faculty of Medicine Universitas Airlangga, and Institute of Tropical Disease (ITD) Universitas Airlangga Surabaya.

This study used male *Rattus novergicus*, age 3–4 months, weight ± 200 grams, and declared healthy on physical examination by veterinarian. Materials tested were silver nano-particles from Aquasil brand produced by Nanonash Pars Company in gel form with 15 µg/ml concentration. Nine *Rattus novergicus* were divided into three groups. The incision was made on each group in the anterior

mandibular gingiva, extending from interdental gingiva of the mandibular central insisiv downwardly along for 5 mm in length and 2 mm in depth. After the incision, 15 µg/ml silver nano-particles gel was topically applied into group A as much as ± 1 ml and then was followed by suturing process on the wound to prevent silver nano-particles gel leaked out from the wound area, and decapitation on the day 3 after exposure process of silver nano-particles gel application. The same steps including slicing process, gel application, and suturing process are also performed in group B, followed by decapitation on the day 5 after exposure process of silver nano-particles gel application. The incision of group C was made without followed by the application process of silver nano-particles gel 15 µg/ml, and then continued by suturing process and decapitation on the day 3 after the slicing process and suturing (control). Decapitation control group was only given on the day 3 because in the normal condition of healing process (without any supporting materials for healing process), is estimated that the cells death through apoptosis will appear 24-72 hours after the incident lesion.¹⁰ For the treatment groups, in addition to decapitation on day 3, they were also given decapitation on day 5 as the healing process could occur faster or slower than in normal condition due to the silver nano-particles exposure. The examination of caspase 3 was conducted by using immunohistochemistry test, and then was observed by using light microscope with 400x magnification. Comparative test independent t-test was used to examine the significant difference between treatment groups and control groups.

RESULTS

Table 1 shows the results of 15 µg/ml silver nano-particles gel exposure on caspase-3 expression of fibroblasts research (Table 1). The highest average of caspase-3 expressions were found in control group. The following bar chart shows the mean value of caspase-3 expressions of fibroblasts in treatment group on the day-3, day-5 (Figure 1).

Figure 2 shows the result of immunohistochemical examination. Thick and long brown colour lines pointed by the small arrows depict the form of fibroblast cells indicating caspase-3 expression. On the day-3, caspase-3

Table 1. The mean and standard deviation of caspase-3 expression in fibroblasts on day-3 and day-5

Group	Group name	Day-3			p	Day-5			p	
		Mean (x̄)	±	Standard Deviation (SD)		Mean (x̄)	±	Standard Deviation (SD)		
Treatment	A	5.67	±	0.577	0.009	B	11.33	±	0.577	0.000
Control	C	18.67	±	1.155						

Notes: * There are significant difference (p<0,05).

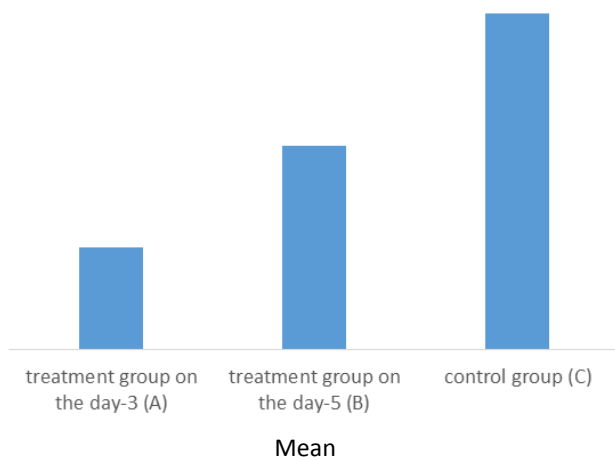


Figure 1. Bar chart of mean value of caspase-3 expressions in fibroblasts on the day-3 and day-5.

Notes: A) treatment group on the day-3; B) treatment group on the day-5; C) control group.

are lesser than of control group (0 $\mu\text{g/ml}$). The significant difference of caspase-3 expressions were also found between treatment group A (on the day-3) and B (on the day-5). This suggests that the exposure of 15 $\mu\text{g/ml}$ silver nano-particles gel is able to suppress the expression of caspase-3 in gingival fibroblasts cells that suffered injury of incision. Typical sign of cells undergoing apoptosis is the expression of caspase-3 (caspase executioner) of the cells. The suppression of caspase-3 expression on gingival fibroblasts cells indicates the reduced number of cells undergoing apoptosis.

Exposure to 15 $\mu\text{g/ml}$ silver nano-particles gel on injury (cuts) were able to suppress the activation of the innate immune response which is the beginning of an inflammatory mechanism in the immune cells activation, the complement system, the identification and the removal of foreign substances, as well as the activation of the adaptive immune system. Phagocytes cells such as polymorphonuclear neutrophils, monocytes,

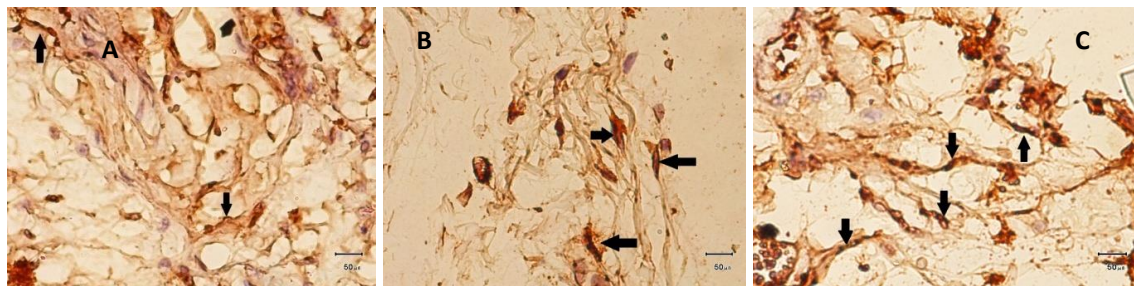


Figure 2. Overview of caspase 3 expression in fibroblasts of each group. Fibroblasts are shown by the small arrows.

Notes: A) treatment group on the day-3; B) treatment group on the day-5; C) control group.

expression on fibroblasts of control group (C) appeared to be denser than of treatment group (A). Caspase-3 expression on fibroblasts of treatment group B (day-5) appeared to be denser than of treatment group A (day-3).

T-test examination was performed after the data were normally distributed by using Kolmogorov-Smirnov test and homogeneous by using Levene test. The result of the comparative test by using t-test on A-C groups showed that the number of expressions of caspase-3 in fibroblasts have significant difference with significance value $p=0.009$. While the result of comparative test by using t-test on B-C groups also have significant difference with significance value $p=0.000$ ($p<0.05$).

DISCUSSION

The research of 15 $\mu\text{g/ml}$ silver nano-particles gel exposure on the expression number of caspase-3 in fibroblasts showed the significant difference of the mean value between treatment group and control group. Caspase-3 expressions in fibroblasts of treatment group

and macrophage are natural immune cells triggered the suppression of pro-inflammatory cytokines release and various systems such as the complement system and acute phase response as the increased oxidative. Macrophage cells as antigen presenting cell (APC) has MHC class II molecules. Through MHC class II, B cells will receive antigen, the antigen is presented to the cells surface to activate T helper cells which then will secrete pro-inflammatory cytokines. The decline of mitochondrial function resulted by cells stress also triggers the activation of gene p-53 as pro-apoptosis gene in mitochondria.¹¹ The activation of gene p-53 followed by the inactivation of protein Bcl-2 and the increased production of Bax will affect the permeability of mitochondrial membrane that can release cytochrome c. The released cytochrome c will be bound by apoptosis activating factor (Apaf-1) and then will form apoptosome. Apoptosome will activate caspase 9 (initial caspase activated by the released cytochrome C), caspase-9 will activate caspase-3 which acts as apoptosis executioner.¹² The number of expressed caspase-3 indicates the number of cells undergoing apoptosis. Caspase

expression will appear in the next 6–9 hours so that the estimated death of cells will appear 24–72 hours after incident lesion.¹⁰

It is concluded that the exposure of 15 µg/ml silver nano-particles gel to gel *Rattus novergicus* gingival fibroblasts decline caspase-3 expression. This suggests that apoptosis of the observed cells through caspase-3 expression is also decreasing.

ACKNOWLEDGEMENT

Gratitude and appreciations are addressed to all staffs of the Laboratory of Pathology Anatomy - Faculty of Dentistry Airlangga University, the Laboratory of Biochemistry - Faculty of Medicine Airlangga University, and Institute of Tropical Disease Airlangga University.

REFERENCES

- Hill J. Colloidal silver: medical uses, toxicology, and manufacture. 3rd ed. Yelm, WA., USA: Clear Springs Press; 2009. p. 68-87.
- Elzey S, Grassion VH. Agglomeration, isolation, and dissolution of commercially manufactured silver nano-particles in aqueous environments. *J Nanopart Res* 2009; 12(5): 1945-58.
- Vermeulen H, van Hattem JM, Versloot NM, Ubink DT. Topical silver for treating infected wounds. *Cochrane Database Systematic Reviews* 2007; Issue 1. Art. No. CD005486.
- Arora S, Jain J, Rajwade JM, Paknikar KM. Cellular responses induced by silver nano-particles :in vitro studies. *Toxicol Lett* 2008; 179(2): 93–100.
- Yoon KY, Hoon BJ, Park JH, Hwang J. Susceptibility constants of *Escherichia coli* and *Bacillus subtilis* to silver and copper nano-particles. *Sci Total Environ* 2007; 373(2-3): 572-5.
- Kumar V, Ramzi SC, Stanley LR. Buku ajar patologi robbins. Edisi 7. Vol. 1. Jakarta: Penerbit Buku Kedokteran EGC; 2007. p. 130-59.
- Hussain SM, Hess KL, Gearhart JM, Geiss KT, Schlager JJ. In-vitro toxicity of nano-particles in BRL 3A rat liver cells. *Toxicol In-Vitro* 2005; 19: 975-83.
- AshaRani PV, Low Kah Mun G, Hande MP, Valiyaveetil S. Cytotoxicity and genotoxicity of silver nano-particles in lung cells. *ACS Nano* 2009; 3(2): 279-90.
- Vandenabeele P. More than one way to die : apoptosis, necrosis and reactive oxygen damage. *Oncogene* 2006. 18(54): 7719-30.
- Dirnagl U, Iadecola C, Moskowitz MA. Pathobiology of ischaemic stroke: an integrated view. *Trends Neurosci* 2005; 22(9): 391–97.
- Wong ML, Strenberg EM. Immunological assays for understanding neuroimmune interactions. *Arch Neurol* 2000. 57(7): 948-52.
- Amantea D, Nappi G, Bernardi G, Bagetta G, Corasaniti MT. Post-ischemic brain damage: pathophysiology and role of inflammatory mediators. *FEBS Journal* 2008; 276(1): 13–26.