



Vol. 11 No.2 August 2017
ISSN : 1907-5987

DENTA

JURNAL KEDOKTERAN GIGI



SUSUNAN REDAKSI

Pemimpin Umum

Noengki Prameswari

Ketua Penyunting

Dian W Damaiyanti

Sekretaris

Agni Febrina Pargaputri, Carissa Endianasari

Bendahara

Maria Franciska

Penyunting Pelaksana

Fitria Rahmitasari, Kharina Widyowati,
Endah Wahjuningsih, Widyastuti, Rima Parwati Sari, Dwi Andriani

Penyunting Ahli (Mitra Bebestari)

Setyo Harnowo, Arifzan Razak, Soetjipto, Dian Mulawarmanti, Sarianoferni,
Mei Syafriadi, Bambang Sucahyo, Achmad Gunadi,
Udijanto Tedjosongko, Iga Wahyu Ardani

Distribusi

Trias Djohar Wirawan

Jurnal Kedokteran Gigi diterbitkan setiap bulan Februari dan Agustus oleh
Fakultas Kedokteran Gigi Universitas Hang Tuah.

ALAMAT REDAKSI

Cp. Carissa Endianasari

Fakultas Kedokteran Gigi-Universitas Hang Tuah

Jl. Arief Rahman Hakim 150 Surabaya

Telp. 031-5945864, 5945894 psw 219/220 Fax. 031-5946261

E-mail: journal.denta@hangtuah.ac.id/jurnal.denta@gmail.com

<http://journal-denta.hangtuah.ac.id>

DAFTAR ISI

Susunan Redaksi	i
Daftar Isi	ii
Bioviability of Mangrove Leaves Extract (<i>Sonneratia alba</i>) on Fibroblast Cell Line BHK-21 Cell Culture <i>Arlita Gladys Tricia Charyadie, Aprilia, Widyastuti</i>	1
Combination Administration of <i>Stichopus hermannii</i> Gel and Hyperbaric Oxygen Therapy the number of fibroblasts in diabetes mellitus rats with periodontitis <i>Faraziza Maulana, Dian Mulawarmanti, Fanny M.Laihad</i>	9
Effect of Hyperbaric Oxygen Therapy Combined with Golden Sea Cucumber (<i>Stichopus hermannii</i> Powder to the Level Of Blood Glucose Diabetic Wistar Rat Induced Porphyromonasgingivalis) <i>Rafika Rusydia Darojati, Yoifah Rizka, Syamsulina Revianti</i>	18
Effect of <i>Stichopus Hermannii</i> to Bigonial Width on Maxillary Suture Expansion using Cephalometric Analysis <i>Kristin Gaby Rosari, Noengki Prameswari, Lisdiana Mardanus</i>	29
Effectivity of the Gold Sea Cucumber Supplementation (<i>Stichopus hermannii</i>) of Catalase Activity in Wistar Rat's Submandibular with Oral Candidiasis <i>Ajeng Hanun Winny Khairina, Syamsulina Revianti, Nafi'ah</i>	38
Effectiveness of Chitosan Solution as Denture Cleanser to Inhibit the Growth of <i>Candida albicans</i> on Acrylic, Valplast and Luciton-FRS <i>Anindita Apsari, Vivin Ariestania</i>	48
Efektifitas PRP (Platelet Rich Plasma) Terhadap Peningkatan BMD (Bone Mineral Density) Maksila Pemasangan Implan Gigi dengan Pemeriksaan Radiografi 3 Dimensi (CBCT) <i>Dianty Saptaswari, Widyatuti, Yoifah Rizka Wedarti, Hansen Kurniawan</i>	56
Role of C-type Lectin Receptor to <i>C.albicans</i> on Promotion of Inflammatory Diseases <i>Erna Sulistyani</i>	63

Study of Hyperbaric Oxygen Therapy and Gold sea Cucumber (Stichopus Hermanii) 3% for Collagen Density of Rat's with Diabetes Mellitus Induced by Porphyromonas Gingivalis Bactery	73
<i>Dyah Lestarining R, Dian Mulawarmanti, Widyastuti</i>	
Increasing Performance Treatment Index's Score (PTI) of Elementary School Children in Keputih-Surabaya Through Dental Public Health Warrior Project	83
<i>Aulia Dwi Maharani</i>	
Aesthetic Treatment In Patient With Fractures Of Maxillary Central Incisor Teeth	89
<i>Sinta Puspita</i>	
Long Term Evaluation of Anterior Primary Resin Crown in Pediatric Patient	98
<i>Annisa Listya Paramita, Sandy Aditya Susilo</i>	
The Use of Lip Bumper in Lip Sucking Treatment	104
<i>Yulie Emilda Akwan, Ayulistya Paramita, Eriza Juniar</i>	

CASE REPORT

The Use of Lip Bumper in Lip Sucking Treatment

Yulie Emilda Akwan*, Ayulistya Paramita*, Eriza Juniar*

*Department of Pediatric Dentistry, Faculty of Dentistry, Universitas Hang Tuah Surabaya, Indonesia

ABSTRAK

Background: Oral habits include habit which are continuously done and has the potential to cause defects on teeth and perioral tissues. Lip sucking or biting habits are often found simultaneously or as a substitution of finger sucking. This habit may affect the labial and perioral structures. The habit may take several forms. Two extreme types are mild wetting of the lips with the tongue and pulling the lips into the mouth between the teeth. The lip bumper is a functional device that is used successfully to intercept developing dental and occlusal problems by allowing a proper development of the arch length and width for eruption of the permanent teeth. **Purpose:** This study aimed to re-validate the effectiveness of lip bumper application and habitual therapy in treating the bad habit of lip sucking. **Case Report:** The mother of a 9-year-old girl reported an upper front teeth protrusion and frequent occurrence of mouth ulcer. Further examination revealed that the patient had a habit of lip sucking. **Case Management:** Removable Lip Bumper is used to control lip habits such as lip sucking and to improve mentalis muscle hyperactivity. Such habit was treated with the use of a removable lip bumper and habitual therapy conducted by both parents. Constants reminder and encouragement from the parent to wear the lip bumper is one of the key success factors in this treatment. **Conclusion:** Five months after the initial application of a lip bumper and habitual therapy, the patient overcame the habit of lip sucking.

Keywords: lip bumper, lip sucking, myofunctional therapy

Correspondence: YulieEmildaAkwan, Department of Pediatric Dentistry, Faculty of Dentistry, Hang TuahUniversity, Arif Rahman Hakim 150, Surabaya, Phone 031-5945864, Email: yulieemilda@yahoo.com.

INTRODUCTION

Habit is an automatic response to a particular situation. It usually develops from learning a set of activity, followed by repetition overtime. Repetition results in a more unconscious habit. Some habits associated with the oral cavity can have a negative effect on oral condition and health. It can cause defects in orofacial structures and perceived malicious oral habits, which intervene with the child's physical, emotional, or social functioning. The severity of the ill-effects of a habit depends on the frequency, intensity, and duration in which the habit is practiced¹. Under certain circumstances in which a habit develops and continues after 3 years of age, the development of the teeth will be severely affected, and as a result, malocclusion may occur². Some of these habits are digit sucking, tongue thrusting, mouth breathing, nail biting, lip sucking, and bruxism³.

Oral habits affect the stomognathic system. Occlusion is one of the processes influenced by these habits. The occurrence of malocclusion would eventually affect the development of the teeth, jaws, and soft tissues. Anomalies in the soft tissues surrounding the lip may lead to hypotonic or hypertonic condition. Lip muscle tonus in a resting mandible position should result in a relaxed and constant low-level activity between the upper and lower lips. Malocclusion would disrupt these capabilities and lead to incompetence, which occurs when the lips cannot attain a relaxed shut condition. Usual treatment for such condition is lip muscle practice.

The normal anatomy and function of the lips are important for

speaking, eating, and maintaining a balanced occlusion. Lip sucking, a form of malicious habit, may hinder the formation of such anatomy. Lip sucking may or may not be related to psychological aspect. The habit may take several forms. Two extreme types are (1) mild wetting of the lips with the tongue and (2) pulling the lips into the mouth between the teeth¹.

Lip sucking or biting habits are often found simultaneously or as a substitution of finger sucking. This habit may affect the labial and perioral structures. A child performs this habit by placing his/ her lower lip to hold the upper incisives. This will create a lingual force from the lower incisives and facial force from the upper incisives. The result is upper incisive protrusion and lower incisive retrusion with bigger overjet. The lower lips can show inflammation signs, reddish appearance with teeth marks on it².

Biting of the lower lip is the most common. The habit is correlated to dry lips and lip inflammation. In severe cases, it can cause hypertrophy vermillion and teeth fracture⁴. In patients presenting with lower lip sucking, strong contractions of the orbicularis and mentalis muscles of the lower lips are induced, leading to the proclination of the maxillary teeth and retroclination of the mandibular teeth, increased overjet, maxillary generalized spacing, mandibular incisor irregularity, and deepening of the labiomental sulcus. On the contrary, upper lip sucking may cause restriction of maxillary development and anterior crossbite. The constriction of the upper and lower arch and posterior open bite in patients who present with cheek sucking and biting is normal⁵.

Myofunctional treatment can be performed in patients with the habit of lower lip sucking. The application of a lip bumper is one of the treatments. A lip bumper is a particular appliance that prevents the habitual practice of drawing the lower lip. The bumper makes lip sucking more difficult; thus, it reminds the patient of the bad habit and helps in reducing and overcoming such habit over time. The lip bumper prevents hyperactivity of the mentalis muscles and abnormal force acting on the incisors.

The lip bumper is an orthodontic appliance that can be applied and removed by the patients themselves, and it is made from acrylic and Adam's clasps for molar retention. The device influences the balance between cheeks, lips, and tongue by carrying on the forces from the perioral muscles to the teeth⁶. The bumper holds down the lower anterior teeth and channels the reaction pressure straight to the molar teeth. With the use of the device, the lower anterior teeth will be free of the excessive pressure from the labial and buccal muscles. The bumper channels the pressure and pushes the molar teeth distally. Eventually, this contraction will help change the relationship between the upper and lower molar teeth⁷. The bumper can also be used for the following reasons: (1) correction of lip trap, (2) uprighting molars and anchoring savers, and (3) distalization of molars and reduction of overjet by the proclination of the mandibular incisors⁸.

A lip bumper is usually used for 24 h a day for approximately 100–300 days². In several cases, the device can be used for only 2–3 h during the day and the whole time during the night when the patient sleeps⁶. However, such application may result in discomfort. Thus, proper cooperation between the patient, parents, and dentist is highly required. High motivation and commitment from both the child and parents in stopping the malicious habit are most important in the treatment of malocclusion in children.

The purpose of thus, this study aimed to verify the effectiveness of lip bumper application and habitual therapy in treating the bad habit of lip sucking.

CASE REPORT

A 9 years old girl came to a pediatric dentist accompanied by her mother. The mother reported an upper front teeth protrusion and frequent occurrence of mouth ulcer. The child was not comfortable with her condition. Further examination and discussion with the mother revealed a bad habit of frequent lower lip sucking. The extra oral check of the patient had a brachyfacial, symmetric, and convex profile (Figures 1a and 1b). Her intraoral examination revealed a class I molar relationship. The patient had 2 mm anterior teeth overjet with 7 mm overbite (palatal bite). Moreover, dry lips and a significant protrusion of the upper anterior teeth were observed (Figure 2). Cavities were evident on 55, 54, 65, 36, 75, 84, 85, and 46.

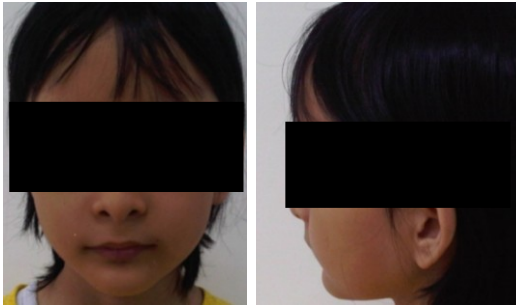


Figure 1. (a) Extraoral facial photograph prior to treatment. (b) Extraoral lateral photograph prior to treatment.

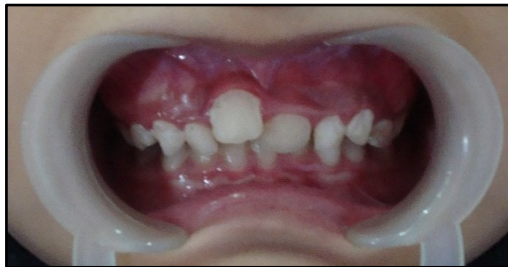

Figure 2. Protrusion of the anterior teeth.

The treatment plan for overcoming the bad habit was established, and a lip bumper was then used. The impaired teeth were first treated, followed by the fabrication and application of a lip bumper. Details about the treatment of the impaired teeth were as follows: fissure sealant on 16 and 26; preventive resin restoration (PRR) type A on 46; PRR type B on 36; GIC filling on 55, 65, 75, 84, and 85; and inlay on 54.

After restoring the impaired teeth, teeth casting was performed. The study model was established, and the work model was developed. The work model helps in designing and constructing the lip bumper (Figures 3a and 3b). The device was inserted 2 weeks after teeth casting (Figure 4). Lip bumper adjustment was carried out smoothly, and both the child and parents were extremely cooperative.

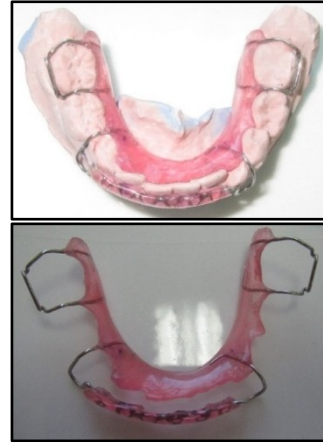


Figure 3. (a) Lower lip bumper (b) Lower lip bumper.

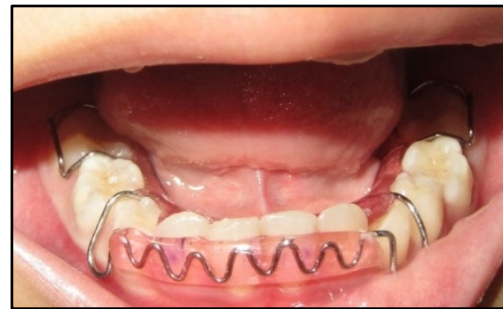

Figure 4. Insertion of a lip bumper in the lower jaw.

The bumper may be used twice a day: 2 h in the morning and during the evening when the child is asleep. The dentist further stated that the time spent on watching TV could be used in applying the bumper in the morning. The parents are encouraged to motivate the child to apply the bumper each night before going to bed and to remove it every morning after waking up. Evaluation or control was conducted once a month. The first evaluation revealed a significant reduction in lip sucking, and finally, after 5 months of application, the patient completely overcame such habit (Figure 5). The treatment was successful. Thus, the protrusion of the upper anterior teeth was then corrected.

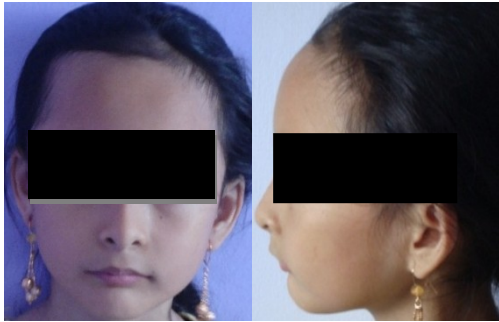

Figure 5. (a) Extraoral facial photograph after 5 months of lip bumper application. (b) Extraoral lateral photograph after 5 months of lip bumper application.

DISCUSSION

Lip sucking is an abnormal habit that may affect the development of the normal lip anatomy. Self-correction helps automatically overcome the habit in children aged below 3 years. By contrast, if children aged greater than 3 years continue the habit of lip sucking, the practice becomes malicious in nature. If such habit continuous during the eruption of the permanent incisors, the damage would become more severe; thus, this harmful habit should be properly treated⁶. Lip bumper and habitual therapy are proper treatment alternatives in overcoming the bad habit of and malocclusion due to lip sucking⁵. A lip bumper is a simple functional appliance, and it is easily applied and removed. Moreover, the patients can well tolerate the device⁹.

In this case, the patient presented with dry lips, protrusion of the upper anterior teeth and deep overbite, and frequent occurrence of mouth ulcer. After examination and discussion with the patient's parents, results showed that the patient had a bad habit of lower lip sucking.

A lip bumper was used to eliminate the habit of lower lip sucking and improve the activity of the labialis and mentalis muscles. Moreover, habitual therapy was conducted by the parents. They remind and motivate the patient to stop the bad habit. In this regard, the habit of lip sucking was treated both medically and psychologically. From a medical perspective, the habit was prevented by shielding the labia using the appliance. The use of the device for 24 h for 6–18 months may be more effective, depending on teeth movement and treatment goal¹⁰. In this case, the use of the device twice a day for 2 h during day time and night time when the patient is asleep also resulted in a significant reduction in lip sucking. Five months after insertion, the patient completely overcame the habit of lower lip sucking, which is a satisfactory result.

The concept behind the use of this appliance is based on the disruption of the equilibrium surrounding the dentition by keeping the musculature of the lower lip and cheeks away from the mandibular teeth, and this allows the lingual forces of the tongue to remain unbalanced, causing forward and lateral expansion of the mandibular dental arch¹¹. In addition, the pressure of the lower lip exerted against the lip bumper during swallowing is transmitted directly to the lower molars. This pressure permits the distalization and distal tipping of the molars, leading to an increase in arch length¹².

CONCLUSION

The lip bumper was effective in treating the habit of lip sucking. Five

months after the initial application of the lip bumper and habitual therapy, the patient completely overcame the habit of lip sucking. After a successful treatment of such habit, the protrusion of the upper anterior teeth was then corrected. In this regard, the bad habit of lip sucking was eliminated by further treatment and long-term stabilization.

REFERENCES

1. Rao, A., *Principles and Practice of Pedodontics*, 3rd edition, New Delhi: Jaypee Brothers Medical Publishers; 2012. p.161-171.
2. Friman, et al. In: Pinkham JR, editor. *Pediatric dentistry infancy through adolescence*. 4th edition. Philadelphia: Elsevier Saunders Co; 2005. p.431-9
3. Shah, A. F., Batra, M., CB, S., Gupta, M., Kadambariambildhok, Kumaret, R., Oral habits and Their Implication. *Ann. Med.* 2014; 1(4):179-186.
4. Shahraki, N., Yassaei, S., Moghadam, M.G., Abnormal oral habits: A review. *J. Dent. Oral Hyg.* 2012; 4(2):12-15.
5. Germec, D., Taner, T.U., Lower lip sucking habit treated with a lip bumper appliance. *Angle Orthod.* 2005; 75(6):1071-1076.
6. Graber, T.M., et al. *Dentofacial orthopedics with functional appliance*. St Louis: CV Mosby; 1993. p.77-75.
7. Robert, H., *A Textbook of Orthodontics*, 4th edition, Philadelphia: Lea and Febriger; 1958. p.211-196.
8. Rao, J.J., *Quick Review Series for BDS Paedodontics* 4th edition, India: Elsevier; 2014. p.159.
9. Soo, N.D., Moore, R.N., A Technique for Measurement of Intraoral Lip Pressures With Lip Bumper Therapy. *Am. J. Orthod.* 99; 1991. p.409-417.
10. Viazis, A.D., *Atlas of Orthodontics: Principles and Clinical Applications*. Philadelphia: W.B Saunders Co; 1993. p.215-217.
11. Murphy, C.C., Magness, W.B., English, J.D., Frazier, B.S.A., Salas, A.M., A longitudinal study of incremental expansion using a mandibular lip bumper. *Angle Orthod.* 2003; 73(4): 396-400.
12. Celentano, G., Longobardi, A., Cannavale, R., Perillo, L., Mandibular lip bumper for molar torque control. *Prog. Orthod.* 2011; 12(1):90-92.